



Lec. 10 Trauma/2

Treatment of Vital Pulp Exposures

Traumatic injuries that expose the pulp in young patients are challenging. Unlike caries exposures, trauma can create many unpredictable responses in the pulp and surrounding tissues. The main goal is to keep the pulp vital whenever possible.

In the management of vital pulp exposure, at least three choices of treatment are available:

- 1) Direct pulp capping.
- 2) Pulpotomy (Partial pulpotomy (Cvek), Full pulpotomy)
- 3) Pulpectomy with endodontic therapy.

1) Direct pulp capping

The treatment of choice is direct pulp capping if:

- a. The patient is seen within an hour or two after the injury,
- b. The vital exposure is small (<1mm).
- c. Sufficient crown remains to retain a temporary restoration to support the capping material and prevent the ingress of oral fluids.

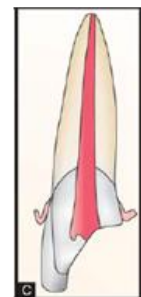Even though the pulp at the exposure site has been exposed to oral fluids for a period of time, the tooth should be isolated with a rubber dam, and the treatment procedure should be completed in a surgically clean environment.

The healthy pulp may survive and repair small injuries even in the presence of a few bacteria, the same as any other connective tissue. The crown and the area of the actual exposure should be washed free of debris, and the pulp should be kept moist before the placement of the pulp-capping material.

Numerous pulp-capping materials have been studied. Pulp capping with conventional bonding materials is now accepted by many, although the procedure is also considered inadvisable by others. Reports on the use of biodentin (which is the first choice and best pulp healing with high success and minimal discoloration), mineral trioxide aggregate MTA (white) may have slight gray discoloration risk but it still excellent), and bone morphogenetic proteins are significant not only for pulp capping but also for general use in endodontic therapy for vital and nonvital teeth.

The prime requisite of pulpal healing is an adequate seal against oral fluids. Therefore, a restoration should be placed immediately to protect the pulp-capping material until the healing process is well advanced. A thin layer of dentin-like material should cover the vital pulp tissue in at least 2 months.

If the injured tooth presents a good indication for direct pulp capping, there is a definite advantage in providing this treatment. The pulp will remain functional and reparative, and dentin will develop and allow the tooth to be restored without loss of normal pulp vitality. If final restoration needs





the use of pulp chamber or the pulp canal for retention, a pulpotomy or pulpectomy is the treatment of choice.

****Calcium hydroxide. Accepted, but inferior long-term seals use it only when bioceramics are unavailable.

Key requirement:

A coronal seal must be placed immediately—microleakage is the major cause of failure.

If the final restoration requires pulp chamber retention → do pulpotomy, not DPC

2) Pulpotomy

- If the pulp exposure in a traumatized immature permanent (open apex) tooth is: large (if even a small pulp exposure exists and the patient did not seek treatment until several hours or days after the injury), or if there is insufficient crown remaining to hold a temporary restoration, the immediate treatment of choice is a shallow pulpotomy or a conventional pulpotomy.
A shallow or partial pulpotomy (Cvek pulpotomy) is preferable if coronal pulp inflammation is not widespread and if a deeper access opening is not needed to help retain the coronal restoration.
- Pulpotomy is also indicated for immature permanent teeth if necrotic pulp tissue is evident at the exposure site with inflammation of the underlying coronal tissue, but a conventional or cervical pulpotomy would be required.
- Yet another indication is trauma to a more mature permanent (closed apex) tooth that has caused both a pulp exposure and a root fracture.
- In addition, a shallow pulpotomy may be the treatment of choice for a complicated fracture of a tooth with a closed apex when definitive treatment can be provided soon after the injury.

The exposure site should be conservatively enlarged, and 1 to 2 mm of coronal pulp tissue should be removed for the shallow pulpotomy or all pulp tissue in the pulp chamber should be removed for the conventional pulpotomy.

When pulp amputation has been completed to the desired level, the pulp chamber should be thoroughly cleaned with copious irrigation.

No visible dentin chips or pulp tissue tags should remain. If the remaining pulp is healthy, hemorrhage will be easy to control with a pledget (a small wad of absorbent cotton) of moist cotton lightly compressed against the tissue. The pulp should also have a bright reddish-pink color and a concave contour (meniscus). A deeper amputation may be necessary if the health of the pulp is questionable. A dressing of biodentin is gently applied to the vital pulp tissue so that it is in passive contact with the pulp. The remaining access opening is filled with a hard-setting, biocompatible material with excellent marginal sealing capability. The crown may then be restored with a separate bonding procedure.



Some experts on pulp therapy recommend conventional pulpectomy and root canal fillings for all teeth treated with calcium hydroxide pulpotomies soon after the root apices close. They view the calcium hydroxide pulpotomy as an interim procedure performed solely to achieve normal root development and apical closure.

They justify the pulpectomy and root canal filling after apical closure as necessary to prevent an exaggerated calcific response that may result in total obliteration of the root canal (calcific metamorphosis or calcific degeneration). This calcific degenerative response had been observed and the researchers agree that it should be intercepted with root canal therapy if possible after apical closure. However, long-term successes can be achieved after calcium hydroxide pulpotomy in which no calcific metamorphosis has been observed.

There is a high probability that long-term success can be achieved without follow-up root canal therapy if:

- 1) Healthy pulp tissue remains in the root canal.
- 2) The coronal pulp tissue is cleanly excised without excessive tissue laceration and tearing.
- 3) If the capping material is placed gently on the pulp tissue at the amputation site without undue pressure.
- 4) If the tooth is adequately sealed.

3) Pulpectomy with Endodontic Treatment

One of the most challenging endodontic procedures is the treatment and subsequent filling of the root canal of a tooth with an open apex. The lumen of the root canal of such an immature tooth is largest at the apex and smallest in the cervical area and is often referred to as a blunderbuss canal. Hermetic sealing of the apex with conventional endodontic techniques is usually impossible without apical surgery. This surgical procedure is traumatic for the young child and should be avoided if possible.

In instances of complicated fractures of young permanent teeth with incomplete root growth and a vital pulp, the pulpotomy technique is the procedure of choice. The successful pulpotomy allows the pulp in the root canal to maintain its vitality and allows the apical portion to continue to develop (apexogenesis).

Occasionally a patient has an acute periapical abscess associated with a traumatized tooth. The trauma may have caused a very small pulp exposure that was overlooked, or the pulp may have been devitalized because of injury or actual severing of the apical vessels. A loss of pulp vitality may have caused interrupted growth of the root canal, and the dentist is faced with the task of treating a canal with an open apex.

If an abscess is present, it must be treated first. If there is acute pain and evidence of swelling of the soft tissues, drainage through the pulp canal will give the child almost immediate relief. A conventional endodontic access opening should be made into the pulp chamber.



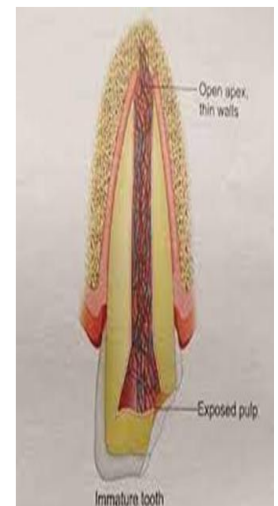
If the pressure required to make the opening into the pulp causes pain, the tooth should be supported by the dentist's fingers. Antibiotic therapy is also generally indicated.

Therapy to Stimulate Root Growth and Apical Repair in Immature Permanent Teeth with Pulpal Necrosis

Apexification

The conventional treatment of pulpless anterior teeth usually requires apical surgery. There is a less traumatic endodontic therapy called apexification, which has been found to be effective in the management of immature, necrotic permanent teeth. The apexification procedure should precede root canal therapy in the management of teeth with irreversibly diseased pulps and open apices.

The procedure has been demonstrated to be successful in repeated clinical trials stimulating the process of root end development, which was interrupted by pulpal necrosis, so that it continues to the point of apical closure. Often a calcific bridge develops just coronal to the apex. When the closure occurs, or when the calcific "plug" is observed in the apical portion, routine endodontic procedures may be completed; the possibility of recurrent periapical pathosis is thus prevented.



The following steps are included in this technique:

- 1) The affected tooth is carefully isolated with a rubber dam, and an access opening is made into the pulp chamber.
- 2) A file is placed in the root canal, and a radiograph is made to establish the root length accurately. It is important to avoid placing the instrument through the apex, which might injure the epithelial diaphragm.
- 3) After the remnants of the pulp have been removed using barbed broaches and files, the canal is flooded with hydrogen peroxide to aid in the removal of debris. The canal is then irrigated with sodium hypochlorite and saline.
- 4) The canal is dried with large paper points and loose cotton.
- 5) A thick paste of calcium hydroxide is transferred to the canal. An endodontic plugger may be used to push the material to the apical end, but excess material should not be forced beyond the apex.
- 6) A cotton pledget is placed over the calcium hydroxide, and the seal is completed with a layer of reinforced zinc oxide–eugenol cement.



The apexification procedure recommended to be completed in two appointments. After instrumentation, irrigation, and drying of the canal during the first appointment, sealing a sterile, dry, cotton pellet in the pulp chamber for 1 to 2 weeks. Placing a calcium hydroxide dressing in the canal is optional at the first appointment.

During the second appointment, the debridement procedures are repeated before the canal is filled with a thick paste of calcium hydroxide and camphoric p-monochlorophenoln (CMCP) or calcium hydroxide in a methylcellulose paste.

Whether the tooth is filled in one or two appointments (or more) should be determined to a large extent by the clinical signs and symptoms present and to a lesser extent by operator convenience. All signs and symptoms of active infection should be eliminated before the canal is filled with the treatment paste. Absence of tenderness to percussion is an especially good sign before the canal is filled.

Because of the wide-open access to periapical tissues, it is not always possible to maintain complete dryness in the root canal. If the canal continues to weep but other signs of infection seem to be controlled after two or three appointments, the dentist may elect to proceed with the calcium hydroxide paste treatment.

As a general rule, the treatment paste is allowed to remain for 6 months. The root canal is then reopened to determine whether the tooth is ready for a conventional gutta-percha filling, as determined by the presence of a "positive stop" when the apical area is probed with a file. Often there is also radiographic evidence of apical closure.

Four successful results of apexification treatment:

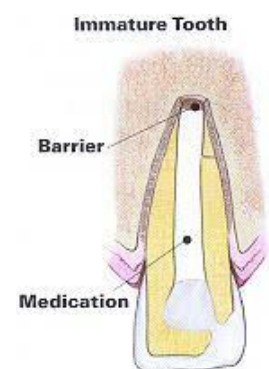
- (1) Continued closure of the canal and apex to a normal appearance.
- (2) A dome-shaped apical closure with the canal retaining a blunderbuss appearance.
- (3) No apparent radiographic change but a positive stop in the apical area.
- (4) A positive stop and radiographic evidence of a barrier coronal to the anatomic apex of the tooth.

If apical closure has not occurred in 6 months, the root canal is retreated with the calcium hydroxide paste. If weeping in the canal was not controlled before the canal was filled, retreatment is recommended 2 or 3 months after the first treatment.

Ideally, the postoperative radiographs should demonstrate continued apical growth and closure as in a normal tooth. When closure has been achieved, the canal is filled in the conventional manner with gutta-percha.

Currently, there seems to be a trend away from the incorporation of antibacterial agents, such as CMCP, into the calcium hydroxide treatment paste.

It is generally agreed that calcium hydroxide is the major ingredient responsible for stimulating the desired calcific closure of the apical area. Calcium hydroxide is also an antibacterial agent. It





may be that CMCP does not enhance the repair; on the other hand, it has not been shown to be detrimental. Certainly, more than one treatment paste has been employed with success.

MTA or Biodentine can be used to form an apical plug for apexification. The root canals that had suffered premature interruption of root development as a consequence of trauma were rinsed with 5% sodium hypochlorite. Calcium hydroxide was then placed in the canals for 1 week.

Following this, the apical portion of the canal (4 mm) was filled with MTA, or Biodentin and the remaining portions of the root canals were closed with thermoplastic gutta-percha. At the 6-month and 1-year follow-ups, the clinical and radiographic appearance of the teeth should show resolution of the periapical lesions. MTA or Biodentine are a valid option for apexification.

Teeth treated by the apexification method are susceptible to fracture because of the brittleness that results from nonvitality and from the relatively thin dentinal walls of the roots. In addition, another important problem with the calcium hydroxide apexification technique is the duration of therapy, which often lasts many months.

Important

Traditional Ca (OH) apexification

- Works but weakens root (fracture risk ↑).
- Requires long-term dressing for 6–18 months.

Regenerative Endodontic Procedures (REPs)

It can be defined as biologically based procedures designed to replace damaged structures, which include dentin, root structures, and cells of the pulp–dentin complex. These procedures provide a biological alternative to induce continuous root development and reduce the risk of fracture associated with traditional treatments of immature teeth with necrotic pulps, such as calcium hydroxide or MTA or biodentin apexification, where the root remains thin and weak.

In the last two decades' improvements in clinical outcome by this technique include healing of periapical pathology, continued development of the root apex, and increased thickness of the root canal wall.

There are three key ingredients for tissue engineering: stem cells, scaffolds, and growth factors.

1) Stem cells are undifferentiated cells that continuously divide. Numerous types of multipotent adult stem cells have been identified from teeth and were hypothesized to play an important role in endodontic regeneration, such as stem cells from apical papilla, dental pulp stem cells, and periodontal ligament stem cells.

2) Scaffold, which provides a matrix for cell organization, proliferation, differentiation, and revascularization. Contemporary REPs have used dentin and blood clots to provide scaffolds in the root canal. However, various scaffolds made of natural or synthetic materials have been proposed in an attempt to create more controlled three-dimensional scaffolds inside the root canal.



3) Growth factors. These biologicals signaling proteins regulate the cellular proliferation, differentiation, and maturation. Current REPs rely mainly on the ability of root canal dentin to release important signaling molecules that may play an important role in regenerative procedures.

Most contemporary REPs rely on the chemical debridement of the root canal, as there is minimal or no mechanical instrumentation. The main objective of chemical debridement is the elimination of microorganisms and necrotic tissues from the root canal system, and this step has been suggested to be the essential factor in successful REPs.

Root canal irrigation with sodium hypochlorite has been suggested to disinfect the root canal and to eliminate the necrotic organic materials from the canal system during REPs. However, higher concentrations of sodium hypochlorite have harmful effects on the differentiation and survival of dental pulp stem cells.

Therefore, 1.5% sodium hypochlorite has been suggested for use in REPs due to its minimal toxic effects on dental pulp stem cells. On the other hand, root canal irrigation with 17% ethylenediaminetetraacetic acid (EDTA) has been recommended as a final irrigation step during REPs. EDTA was suggested to condition the superficial root canal walls, expose the dentin protein matrix, and improve dental pulp stem cell proliferation.

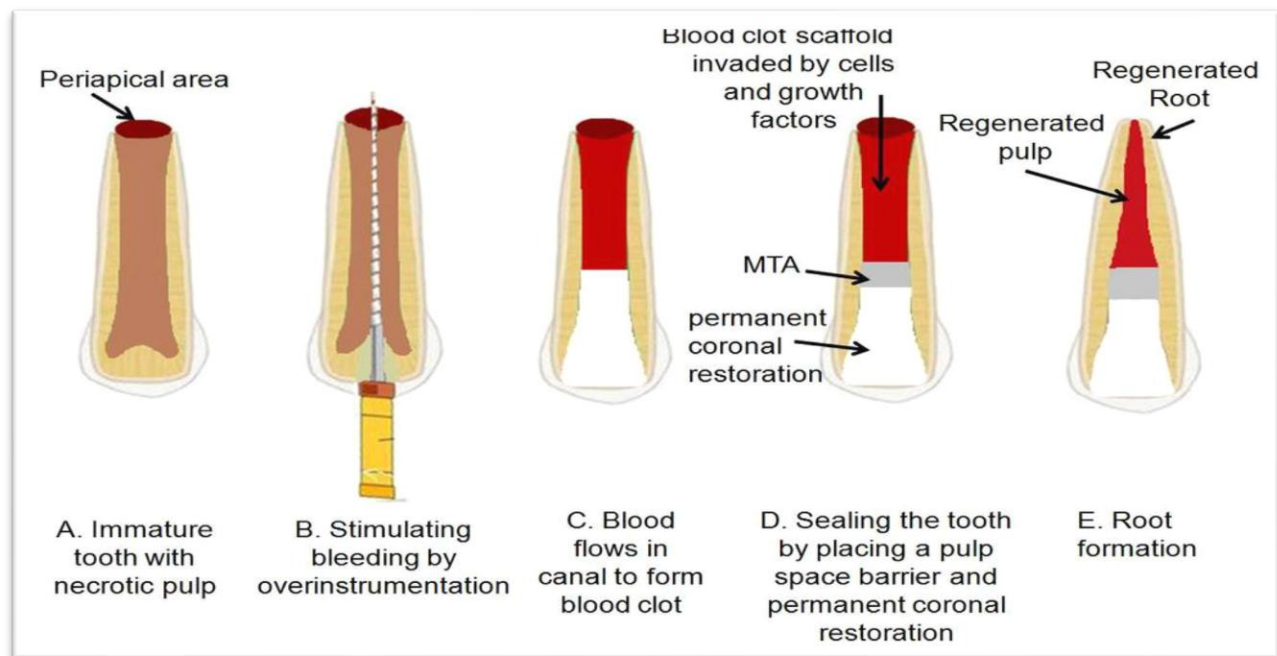
However, intracanal medicaments used in REPs, such as various antibiotic mixtures and calcium hydroxide, have also been suggested to have a role in exposing various dentinal proteins. The application of intracanal medicaments has been adopted in all suggested REPs. The most widely used intracanal medicament in endodontic regeneration is the triple antibiotic paste which is a mixture of water and equal parts of metronidazole, ciprofloxacin, and minocycline.

However, significant tooth discoloration after the application of triple antibiotic paste has been reported to occur due to staining of the dentin by the minocycline present in the paste.

Sealing the pulp chamber with flowable composite resin before the triple antibiotic paste application and maintaining the paste below the cemento-enamel junction have been suggested to minimize the staining effect of the paste.

Others proposed eliminating the minocycline and keeping only metronidazole and ciprofloxacin in the antibiotic paste or substituting the minocycline with another antibiotic, such as clindamycin, cefaclor, or amoxicillin. Recent in vitro studies raised some concerns regarding the cytotoxic effects of various antibiotic combinations used in REPs on the dental pulp stem cells. Therefore, lower concentrations of these antibiotic mixtures (0.1 mg/mL) have been recommended to avoid stem cell toxicity. It is noteworthy that the short-term application of calcium hydroxide paste has also been successfully used in REPs.

The effects of calcium hydroxide paste were found to be less detrimental to stem cells of the apical papillae, as compared with various antibiotic mixtures. A biocompatible disinfection protocol utilizing both irrigation solutions and intracanal medicament to effectively eradicate a root canal infection and create an environment conducive to the proliferation and differentiation of dental pulp stem cells is an important aim to improve the outcomes of REPs.



American Association of Endodontists has recommended the following treatment protocol:-

First Appointment

1. After administration of adequate local anesthesia, the affected tooth is carefully isolated with a rubber dam, and an access opening is made into the pulp chamber.
2. A file is placed 1 mm from the root end in the root canal, and a radiograph is made to establish the root length accurately.
3. Each root canal is slowly irrigated with 20 mL of 1.5% sodium hypochlorite for 5 minutes followed by irrigation with 20 mL of saline for 5 minutes. A closed-end needle or the EndoVac negative pressure irrigation system should always be used to deliver the irrigation solutions during REP, to minimize the possibility of extrusion of irrigants into the periapical space.
4. The canal is dried with large paper points.
5. Antibiotic or calcium hydroxide paste is applied into the canal via a lentulo spiral or Centrix syringe. For antibiotic paste, mix equal portions of metronidazole, ciprofloxacin, and minocycline with sterile water to create a pasty consistency. However, a lower concentration of antibiotics is preferable (0.1 mg/mL).
6. Seal the root canal with 3 to 4-mm Cavit, followed by a temporary restorative material, and dismiss the patient for 1 to 4 weeks.



Second Appointment

1. Evaluate the affected tooth response to initial treatment. If there are no clinical signs or symptoms of persistent infection, proceed with step 2.

If there is evidence (e.g., sinus tract, percussion sensitivity), consider additional treatment with NaOCl irrigation and the antibiotic intracanal medicament and recall the patient after 1 to 4 weeks.

2. After administration of adequate local anesthesia, **3% mepivacaine (no epinephrine)**, the affected tooth is isolated with a rubber dam.

3. The root canal is accessed, and the intracanal paste is removed by gentle irrigation with **20 mL of 17% EDTA** followed by normal saline, using a closed-end needle or the EndoVac system.

4. The canal is dried with large paper points.

5. Bleeding is induced into the root canal by over instrumentation with an endodontic file.

6. Bleeding is stopped 3 mm from the cemento-enamel junction.

7. A collagen matrix such as **CollaPlug** is placed at **3 mm** below the cemento-enamel junction.

8. A **3- to 4-mm layer of white MTA** is placed, followed by reinforced glass ionomer and permanent coronal restoration. Glass ionomer may be a potential alternative to MTA in cases where crown discoloration is a potential aesthetic concern.

Cases treated with REPs need to be followed up at 3 months, 6 months, and annually thereafter for 4 years. Absence of signs and symptoms of pathosis, as well as radiographic evidence of bony healing within 2 years of treatment, should be expected. However, the clinical expectations for REPs are not well defined.

The degree of success of REPs can be measured by the achievement of a primary goal, which is the absence of symptoms and radiographic evidence of periapical healing.

Secondary desirable yet not essential goals are increases in the thickness of the root walls and/ or increases in the length of the immature root.

Tertiary goals, indicating a high level of success, include regaining the vitality of the tooth. Clinical signs and symptoms after REPs, such as swelling, pain, or an increase in radiolucency, indicate failure of REPs, and more traditional treatment modalities should be initiated, such as MTA apexification.



*****Important*****

Current irrigants recommendations

- 1.5% NaOCl (minimizes stem cell toxicity)
- 20 mL per canal, 5 minutes
- Final irrigation: 17% EDTA (liberates dentin bioactive molecules)

Intracanal medicament

- Low-concentration (0.1 mg/mL) double antibiotic paste (Metro + Cipro)
- Avoid minocycline (severe discoloration).
- Ca(OH)₂ is acceptable and less cytotoxic in vitro.

Indicators of success

- **Primary:** No symptoms + radiographic healing
- **Secondary:** Root lengthening + thickening
- **Tertiary:** Positive vitality testing (rare but possible).